


JAVMA

In This Issue

SEPTEMBER 1, 2019



President's Column

Continuing our path forward: Working for you, advancing animal health

[Read more](#)

JAVMA News

Symposium attendees discussed how to improve access to veterinary care for animals owned by people who now cannot afford it. In other news, cardiologist and author Barbara Natterson-Horowitz, MD, delivered the AVMA Convention's keynote address on the commonalities of humans and other animal species.

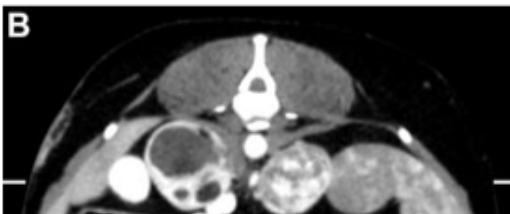[Read more](#)

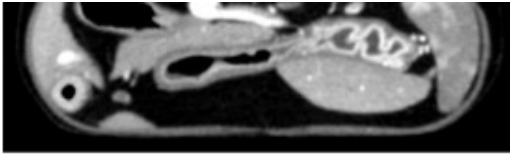
Letters to the Editor

- Experiences with passive restraint of cats
- Setting expectations for animal behavior cases
- Maintaining our commitment to our clients and patients
- Veterinary reporting of animal abuse and neglect
- Ingestion of *Sophora secundiflora* by dogs

[Read more](#)

What Is Your Diagnosis?





Postcontrast transverse CT image of the abdomen of a dog with progressive bilateral adrenomegaly.

[Read more](#)

What Is Your Neurologic Diagnosis?

A 1-year-old Labrador Retriever with a left-sided head tilt was referred for neurologic examination after the tilt failed to resolve following successful treatment of otitis externa.

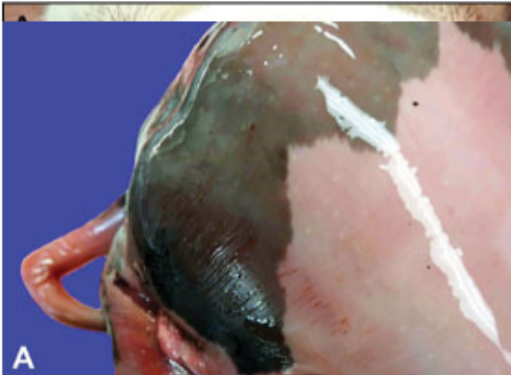
[Read more](#)

ECG of the Month

A 3- to 6-month-old Scottish Fold cat with an unknown medical history was referred to cardiology specialists for evaluation of a heart murmur that had been detected by a primary care veterinarian.

[Read more](#)

Pathology in Practice



Photograph of the skin covering the outer thigh muscles of an aborted Holstein bull fetus. The dam had no history of disease or periparturient clinical abnormalities, and the herd had no other recent abortions.

[Read more](#)

COMMENTARY

Thinking like a futurist could help the veterinary profession

From 1910 through 1930, the veterinary profession went through a time of great upheaval as automobiles displaced horses as the primary means of transportation and equine veterinarians were forced to adapt. Use of foresight tools can help prepare and control for similar upheaval in the future by examining the forces shaping the veterinary profession now and in the future.

[Read more](#)

Role of carbohydrates in the health of dogs

Despite the concerns of some owners, there appears to be no association between dietary carbohydrates and the development of obesity, diabetes mellitus, cancer, or adverse food reactions in dogs. Indeed, diet, and carbohydrates in particular, can be important in the treatment of these conditions.

[Read more](#)

Extralabel drug use in wildlife and game animals

Because few drugs have been approved by the US FDA for use in nondomestic animal species, extralabel drug use in wildlife and game animals is common. Veterinarians should be aware of the requirements outlined by AMDUCA for legal ELDU to safeguard the human food supply while continuing to promote the health and welfare of wildlife species.

[Read more](#)

SMALL ANIMALS

Factors associated with dehiscence and mortality rates following gastrointestinal surgery in dogs

Multivariate analyses controlling for several patient factors revealed that dogs with an American Society of Anesthesiologists physical status ≥ 3 (vs < 3) were more likely to develop dehiscence after gastrointestinal surgery and that dogs with a high plasma lactate concentration were less likely to survive for at least 2 weeks than were other dogs.

[Read more](#)

Lung ultrasonography findings in dogs with various underlying causes of cough

Findings of a retrospective study suggested that in dogs with a clinical history of cough, lung ultrasonography could be diagnostically useful, particularly to help exclude the possibility of underlying cardiogenic pulmonary edema.

[Read more](#)

RUMINANTS

Frontal sinusitis in adult beef bulls: 18 cases (1999-2014)

In a retrospective case series involving 18 beef bulls with frontal sinusitis unrelated to dehorning, only 8 bulls had nasal discharge on initial evaluation, only 7 with a measured rectal temperature were febrile, and the most common owner complaint was nonspecific signs. All 14 bulls with follow-up information recovered fully.

[Read more](#)

Suprascapular nerve decompression for treatment of neuropathy in a bucking bull

A bucking bull that had developed lameness of a forelimb after exiting a rodeo chute was found via ultrasonography and electromyography to have suprascapular neuropathy. Surgical decompression of the affected nerve was successful, and by 4 months after the procedure, the bull had returned to bucking.

[Read more](#)

SPECIAL REPORT

Suicides and deaths of undetermined intent among veterinary professionals from 2003 through 2014

An analysis of death records for 197 veterinary professionals and 5 veterinary students revealed that the most commonly identified mechanism of death was self-poisoning (46% [86/189]) and that 18 of 73 (25%) veterinarians died of pentobarbital poisoning specifically.

[Read more](#)

Follow Us:   

CONTACT US: Please do not reply directly to this newsletter. Comments and questions should be directed to Carol Obodzinski, JAVMA Administrative Assistant, at JAVMA@avma.org